

## Ectoparasites on Reintroduced Roe Deer *Capreolus capreolus* in Israel

Arian D. Wallach,<sup>1</sup> Uri Shanas,<sup>1,2</sup> Kosta Y. Mumcuoglu,<sup>3</sup> and Moshe Inbar<sup>1,4</sup> <sup>1</sup>Department of Evolutionary and Environmental Biology, University of Haifa, Mount Carmel, Haifa 31905, Israel; <sup>2</sup>Department of Biology, University of Haifa-Oranim, Tivon, Israel; <sup>3</sup>Department of Parasitology, Hebrew University-Hadassah Medical School, Jerusalem, Israel; <sup>4</sup>Corresponding author (email: minbar@research.haifa.ac.il)

**ABSTRACT:** The ectoparasite fauna of reintroduced roe deer (*Capreolus capreolus*) was surveyed in a Mediterranean forest in Israel. Ectoparasites were collected from four female hand-reared deer during 2004 and 2005. Seasonality, predilection sites of infestation, and the apparent effect of the parasites are presented. This is the first study of roe deer parasites in the East Mediterranean. The ectoparasite fauna included three hippoboscid fly (*Lipoptena capreoli*, *Hippobosca equina*, and *Hippobosca longipennis*), four tick (*Rhipicephalus sanguineus*, *Rhipicephalus turanicus*, *Rhipicephalus kohlsi*, and *Hyalomma marginatum*), and one unidentified trombiculid mite species. For most of these ectoparasites, this is the first record on roe deer. All ectoparasite species were documented in Israel prior to the reintroduction program; exotic ectoparasites were not detected.

**Key words:** *Capreolus*, ectoparasites, hand-reared, Mediterranean forest, ticks.

The roe deer (*Capreolus capreolus*) is widespread in Europe (Andersen et al., 1998), but has been extinct in the East Mediterranean region since the beginning of the 20th century (Harrison and Bates, 1991). A reintroduction program for roe deer was initiated in Israel in 1991, with deer imported from France, Italy, and Hungary.

It has been suggested that in Europe roe deer may play an important role in the maintenance of tick populations and the persistence of tick-borne diseases (Gerth et al., 1995; Alberdi et al., 2000; see also Keysary et al., 2007). However, roe deer have been found to be incompetent reservoirs for many vector-borne zoonotic diseases, such as Lyme disease (Jaenson and Talleklint, 1992).

Reintroduction programs may accelerate the spread of parasites, as animals are moved between regions, potentially introducing foreign parasites and diseases

(Gogan, 1990; Yeruham et al., 1994). As part of a study on roe deer reintroduction to Israel, we hand-reared four does for close observation and approachability in semi-free-ranging conditions (Wallach et al., 2007a, b). The aim of this study was to identify the ectoparasites of roe deer recently reintroduced to Israel, and to study their seasonality, predilection sites of infestation and health implications.

Four female roe deer born in the captive breeding colony were hand-reared, and at the age of 6–8 mo released into a 10-ha fenced section of a natural Mediterranean forest within the boundaries of the Hai-Bar Nature Reserve in the Carmel ridge (34°97'N, 32°72'E). The hand-reared deer were easily observed and handled by their keeper (Wallach et al., 2007a).

The survey was conducted fortnightly from January 2004 to February 2005. No insecticides, acaricides, or repellents were used to control parasite loads during the survey. Ectoparasites were collected from the coat and skin of the deer, and preserved in 70% ethyl alcohol. Between collections, ticks were removed and discarded to maintain the deer's health. The site of infestation on the animal was recorded for each ectoparasite species. Because deer were observed closely on a daily basis, we also recorded their behavioral reactions and any external symptoms that were associated with the ectoparasites.

Table 1 shows the distribution and preferred areas of ectoparasites on the deer's body. The phenology of the parasites is given in Figure 1.

The wingless louse fly *Lipoptena capreoli* Rondani was the most abundant ectoparasite ( $n=79$ ), found throughout

TABLE 1. Ectoparasites found on the roe deer and their distribution on the host body.

Ectoparasite species	Preferred body part
<i>Lipoptena capreoli</i>	Entire body, excluding the head and lower legs
<i>Hippobosca equina</i>	Entire body (excluding lower legs). Prefers the ears, neck and inner thighs
<i>Hippobosca longipennis</i>	Entire body (excluding lower legs). Prefers the ears, neck and inner thighs
<i>Hyalomma marginatum</i>	Anus only
<i>Rhipicephalus kohlsi</i>	Ears mostly; one was found on the face
<i>Rhipicephalus sanguineus</i>	A single specimen was found on the anus
<i>Rhipicephalus turanicus</i>	Ears only
Trombiculid mites	Axilla region only

the year, but especially in summer. It was the first ectoparasite to infest roe deer, being found on fawns within 2 days of birth. It was observed that the presence of *L. capreoli* stimulate intensive licking, and the flies were often caught by the deer's tongue and swallowed. High numbers of *L. capreoli* coincided with hair loss on the sides of the chest and thighs. In Israel, this species is associated with hosts such as mountain gazelles, goats, cattle, camels, and dogs (Theodor, 1975; Theodor and Costa, 1967; Yeruham et al., 1999). As this ectoparasite reaches high density on deer, its effect deserves further examination. *Lipoptena cervi* Linnaeus is common on roe deer in Europe (Kaczmarek and Kolodziej, 1994), but has not been found in Israel.

*Hippobosca equina* Linnaeus also occurred throughout the year ( $n=43$ ) most

notably in spring and autumn. The dog fly, *Hippobosca longipennis* Fabricius, was less common ( $n=17$ ) and appeared mostly in summer. The deer would generally ignore these parasites, though rarely they seemed to cause signs of irritation such as scratching, running, and twitching.

Seventy-four ticks were collected and identified. *Rhipicephalus turanicus* Pomerantsev was most common; all 43 specimens collected were adults, of which 28 were females (female-biased sex ratio,  $\chi^2=3.9$ ,  $df=1$ ,  $P<0.05$ ) and all were found on the ears. *Rhipicephalus kohlsi* (Hoogstraal & Kaiser) appeared only in late autumn ( $n=16$ ); 15 were nymphs and one was an adult female. *Hyalomma marginatum* Koch was found on the deer during April–August. All 14 specimens collected were adults (10 males). This was the only species that caused superficial wounds in

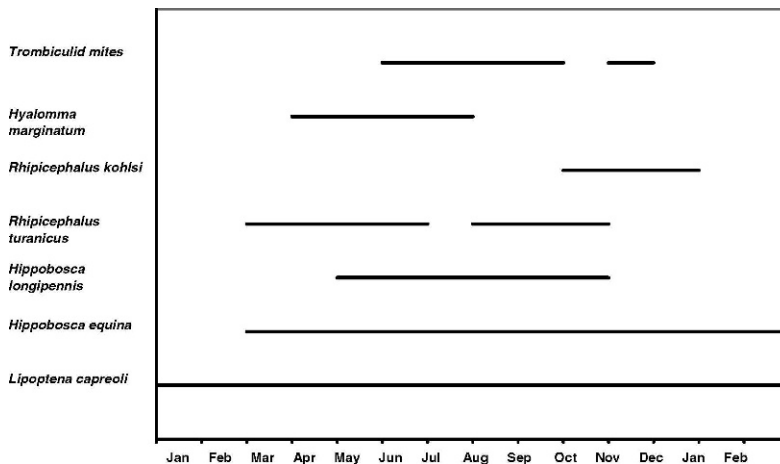


FIGURE 1. Seasonality of ectoparasites found on the deer's body.

the area of infestation. A single adult male of *Rhipicephalus sanguineus* Latreille was found in May 2004 on the deer's anal area. Finally, larvae of unidentified trombiculid mites were found between June and November. Clusters of approximately 20 individuals on an area of ca. 4 mm in diameter were found around the deer's axilla. No irritation or any other ill effects were observed.

All ectoparasite species detected in this study had been documented in Israel prior to the reintroduction (Theodor and Costa, 1967). Thus, the reintroduced deer did not maintain introduced ectoparasites, but served as an alternative host for endemic species.

The widely distributed ticks *R. turanicus*, *R. sanguineus*, and *H. marginatum* are common in Israel on various domestic and wild animals (Mumcuoglu et al., 1993; Yeruham et al., 1999). Only *R. kohlsi* is documented here for the first time in the Carmel region in Israel (Feldman-Muh-sam and Shechter, 1970). *Hyalomma marginatum* was the only tick observed to cause lesions. This was most apparent in two captive male roe deer in the breeding colony, which required veterinary treatment because of secondary infections in the anal area caused by the presence of approximately 20 of these ticks. In the four hand-reared does, these ticks caused superficial wounds but were always removed quickly enough to avoid infection.

The reintroduction of roe deer may have implications for disease transmission in this region. Recently, sequences from of *Anaplasma phagocytophilum* (AP-variant I strain) 16S rRNA gene were found for the first time in Israel from three tick species (*H. marginatum*, *R. turanicus*, and *R. kohlsi*) collected on the same roe deer as the current study (Keysary et al., 2007). *Rhipicephalus sanguineus* and *R. turanicus* are known vectors of *Rickettsia conorii* (Mumcuoglu et al., 1993; Guberman et al., 1996). In addition, *R. sanguineus* is a known vector of *Ehrlichia canis*, *Babesia canis*, and *Hepatozoon canis* (Smith et al.,

1976; Taboada and Merchant, 1991; Baneth et al., 2007). Lyme disease and the known Ixodes vectors have not been detected in Israel.

Monitoring ectoparasites on hand-reared animals has several advantages. Although time limited (14 mo), the richness of parasite species detected here was similar to those found in longer surveys in the region (e.g., Yeruham et al., 1999) and in other studies of roe deer (Sugár, 1997). In addition, the intimate relationships with the deer provided details about the infestation site, phenology, and the impact on the deer. Nevertheless, the effect of the parasites on the deer reported here is probably underestimated because the parasites were routinely removed.

This study suggests that the reintroduced deer serve only as hosts for the generalist ectoparasites already found on other wild and domestic animals in the region. The potential role of roe deer in ectoparasite-borne diseases deserves future attention. Detailed understanding of a species' accompanying parasites should be made an integral part of reintroduction studies.

We thank the Hai Bar Carmel staff, A. Lurie and Y. Maklade, for their devoted help. We are grateful to Dr. A. Freidberg for identification of the hippoboscids. We also thank Dr. M. Samish and the late Dr. I. Yeruham for advice, and anonymous reviewers for helpful comments. This work was partly funded by the Rieger Foundation.

#### LITERATURE CITED

- ALBERDI, M. P., A. R. WALKER, AND K. A. URQUHART. 2000. Field evidence that roe deer (*Capreolus capreolus*) are a natural host for *Ehrlichia phagocytophila*. *Epidemiology and Infection* 124: 315–323.
- ANDERSEN, R., P. DUNCAN, AND J. D. LINNELL (eds.). The European roe deer: The biology of success. Scandinavian University Press, Oslo, Norway.
- BANETH, G., M. SAMISH, AND V. SHKAP. 2007. Life cycle of *Hepatozoon canis* (Apicomplexa: Adeleorina: Hepatozoidae) in the tick *Rhipicephalus sanguineus* and domestic dog (*Canis familiaris*). *Journal of Parasitology* 93: 283–299.

- FELDMAN-MUHSAM, B., AND R. SHECHTER. 1970. Some notes on the genus *Boophilus* (Ixodidae), with special reference to species found in Israel. *Journal of Medical Entomology* 7: 677–686.
- GERTH, H. J., D. GRIMSHANDL, B. STAGE, G. DOLLER, AND C. KUNZ. 1995. Roe deer as sentinels for endemicity of tick-borne encephalitis virus. *Epidemiology and Infection* 115: 355–365.
- GOGAN, P. J. P. 1990. Considerations in the reintroduction of native mammalian species to restore natural ecosystems. *Natural Areas Journal* 10: 210–217.
- GUBERMAN, D., K. Y. MUMCUOGLU, A. KEYSARI, I. IOFFE-USPENSKY, J. MILLER, AND R. GALUN. 1996. Prevalence of spotted fever group Rickettsiae in ticks from southern Israel. *Journal of Medical Entomology* 33: 979–982.
- HARRISON, D. L., AND P. J. J. BATES. 1991. The mammals of Arabia. 2nd Edition. Harrison Zoological Museum, Kent, United Kingdom, pp. 204–209.
- JAENSON, T. G., AND L. TALLEKLINT. 1992. Incompetence of roe deer as reservoirs of the Lyme borreliosis spirochete. *Journal of Medical Entomology* 29: 813–817.
- KACZMAREK, S., AND R. KOŁODZIEJ. 1994. Parasite arthropods of some species of wild mammals from middle Pomerania. *Wiadomości Parazytologiczne* 40: 103–106. [Polish with English summary]
- KEYSARY, A., R. MASSUNG, M. INBAR, A. D. WALLACH, U. SHANAS, K. Y. MUMCUOGLU, AND T. WANER. 2007. First direct evidence of the prevalence of *Anaplasma phagocytophilum* in Israel. *Emerging Infectious Diseases* 13: 1411–1412.
- MUMCUOGLU, K. Y., K. FRISH, B. SAROV, E. MANOR, E. GROSS, Z. GAT, AND R. GALUN. 1993. Ecological studies on the brown dog tick *Rhipicephalus sanguineus* (Acari: Ixodidae) in southern Israel and its relationship to spotted fever group Rickettsiae. *Journal of Medical Entomology* 30: 114–121.
- SMITH, R. D., D. M. SELLS, E. H. STEPHERSON, M. RISTIC, AND D. L. HUXSOLL. 1976. Development of *Ehrlichia canis*, causative agent of canine ehrlichiosis, in the tick *Rhipicephalus sanguineus* and its differentiation from a symbiotic rickettsia. *American Journal of Veterinary Research* 37: 119–126.
- SUGÁR, L. 1997. Deer and their parasites: Disease or coexistence? *Parasitologia* 39: 297–301.
- TABOADA, J., AND S. R. MERCHANT. 1991. Babesiosis of companion animals and man. *Veterinary Clinics of North America. Small Animal Practice* 21: 103–123.
- THEODOR, O. 1975. Diptera Pupara. In *Fauna Palaestina—Insecta 1*. The Israel Academy of Sciences and Humanities, Jerusalem, Israel.
- , AND M. COSTA. 1967. A survey of the parasites of wild mammals and birds in Israel. The Israel Academy of Sciences and Humanities.
- WALLACH, A. D., M. INBAR, R. LAMBERT, S. COHEN, AND U. SHANAS. 2007a. Hand rearing roe deer (*Capreolus capreolus*): Practice and research potential. *International Zoo Yearbook* 41: 183–193.
- , ———, M. SCANTLEBURY, J. R. SPEAKMAN, AND U. SHANAS. 2007b. Water constraints on roe deer reintroduction in dry Mediterranean habitats. *Canadian Journal of Zoology* 85: 1182–1192.
- YERUHAM, I., S. ROSEN, B. YACOBSON, AND A. NYSKA. 1994. Severe infestation of imported roe deer (*Capreolus capreolus coxi*) by *Hypoderma diana* (Diptera: Hypodermatidae). *Journal of Wildlife Diseases* 30: 552–553.
- , ———, A. HADANI, AND Y. BRAVERMAN. 1999. Arthropod parasites of Nubian ibex (*Capra ibex nubiana*) and gazelles (*Gazella gazella*) in Israel. *Veterinary Parasitology* 83: 167–173.

Received for publication 14 March 2007.